

Baldness in a canary (*Serinus canaria*) associated with *Pseudomonas osteomyelitis*

Razmyar, J.¹, Dezfoulan, O.², Peighambari, S. M.^{1*}, Vajhi, A.¹, Zahraei Salehi, T.³, Shojadoost, B.¹

¹Departments of Clinical Sciences, ²Pathology, ³Microbiology and Immunology, Faculty of Veterinary Medicine, University of Tehran, Tehran-Iran.

Abstract: Radiography of a 2-year-old canary (*Serinus canaria*) presented to the bird clinic with head alopecia, anorexia, emaciation and dropped lower beak revealed lower beak fracture and skull bone osteomyelitis. Despite providing the supportive care management, the bird died. Histopathological sections confirmed radiographic findings and bacteriological examinations resulted in the profuse pure growth of *Pseudomonas aeruginosa*. This is the first report of the bone infection associated with *P. aeruginosa* leading to baldness in canaries. *J.Vet.Res.* 62,2:11-13,2007.

Key words: *Pseudomonas aeruginosa*, canary, osteomyelitis, baldness, birds.

Introduction

The loss of head feathers in pet birds may occur due to various conditions such as: mite infestation, dermatophytes, necrosis, environmental factors and infection with pathogens (8). *Pseudomonas aeruginosa*, a ubiquitous and an opportunist pathogen, has been incriminated in both localized and systemic infections in birds (1,2,3,9,10). The organism may produce respiratory infections, sinusitis, keratitis, keratoconjunctivitis, or septicemia (1,2,9,10). It may cause mortality in embryos and newly hatched birds (2). *Pseudomonas aeruginosa* is a known cause of osteomyelitis in man (5, 6) but only a few reports on such infection in animals have been documented (7). Osteomyelitis associated with *P. aeruginosa* has not been reported for birds.

Case Report

A 2-year-old canary, housed alone, was presented to the clinic to be suffering from dropped-lower beak, dyspnea, recumbency, breast muscle atrophy, and obvious alopecia on the back part of the head.

Owner observations indicated the development of

anorexia and the loss of head feathers starting 2 weeks ago. Having no experience, she tried hand feeding the bird for 3 days but the bird got into worse condition leading to dropped-lower beak.

Radiographs prepared from 4 sides of the head demonstrated fracture of the lower mandible and osteomyelitis. After radiography, intensive care and routine emergency works were started but it could not help and the bird died. Necropsy revealed distended gall bladder, empty intestine, and pulmonary congestion. On the skull bone surface, an elastic occipital bone and a row of white-grayish bubble like protuberances were found.

Histopathological examinations of the brain, the skull bone and the surrounding tissues showed the brain structure as intact but inflammation of the bone (osteitis), bone marrow (myelitis) and the subcutaneous tissue. The disfigured bone tissue showing the necrosis of osteocytes and superimposition of acute inflammation in the marrow spaces was an indication of the acute bacterial osteomyelitis.

Accumulation of the exudates in the intertrabecular spaces, which filled the medullary cavity, was obvious (Fig 1). The pus consisted of high numbers of heterophils and macrophages accompanied by the thick strands of eosinophilic

*Corresponding author's email: mpeigham@ut.ac.ir, Tel: 021-66923510, Fax:021-66933222



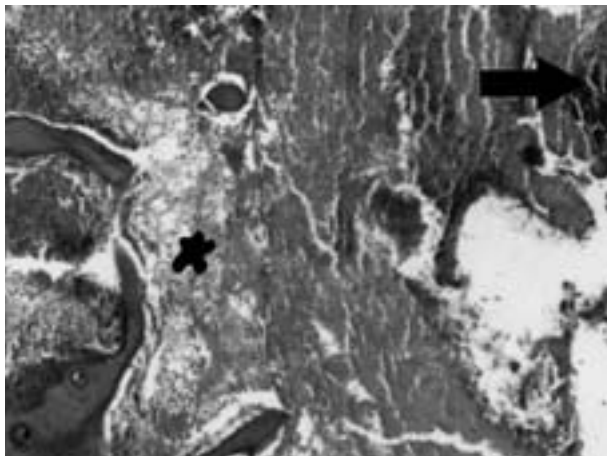


Figure 1. Bacterial osteomyelitis. Accumulation of the exudates in the intertrabecular spaces, which fills the medullar cavity, is shown. The pus consists of large numbers of heterophils and macrophages accompanied by the thin strands (star), thick strands (short thin arrow) of eosinophilic fibrinous material and the clumps of bacteria (thick arrow). Necrosis of trabeculae margins are also evident (*HandE*, 100x).

fibrinous material and the clumps of bacteria. Periosteum was also observed to be greatly thickened due to fibroblast proliferation, collagenesis and infiltration of mononuclear cells (not shown in the figures). Invasion of inflammatory cells toward the margin and necrosis of trabeculae of the spongy bone were evident (Fig. 2). Many dispersed bone fragments rimmed by inflammatory cells and delicate threads of fibrin were observed (Fig. 3). Interestingly, no changes were found in the brain.

Samples taken aseptically from the priosteal and the skull bone lesions were sent for bacteriological

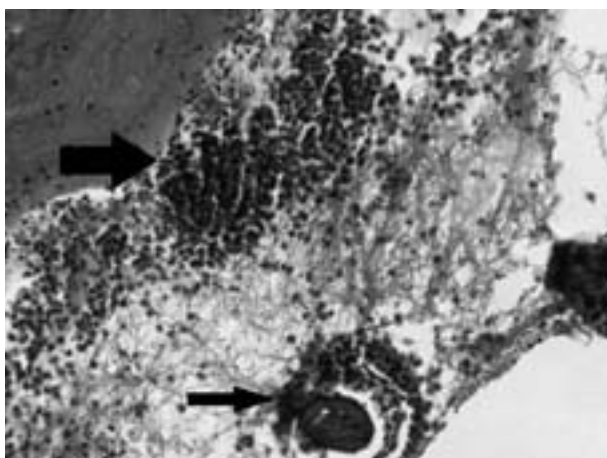


Figure 3. Osteomyelitis of dispersed bone fragments. Bone fragments sequestered and surrounded by inflammatory cells (thin arrow) and clumps of bacteria and infiltration of leukocytes are demonstrated (thick arrow) (*HandE*, 250x).

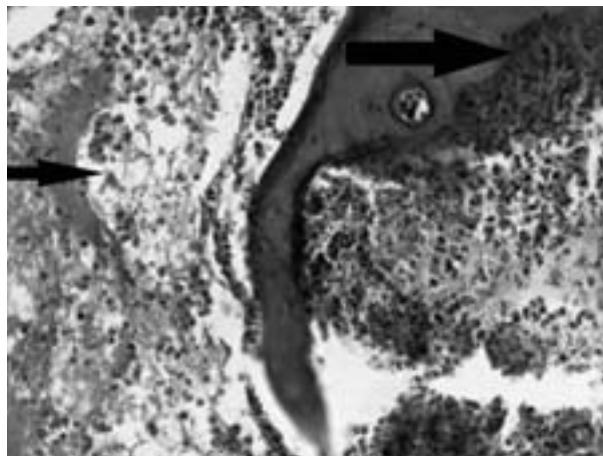


Figure 2. The trabeculae of the spongy bone. The presence of the fine strands of fibrin and leukocytes (small arrow), invasion of inflammatory cells toward the margin and necrosis of trabeculae (medium arrow), and thick strands of fibrinous material (large arrow) are shown (*HandE*, 250x).

examination. The culture resulted in profuse pure growth of gram-negative rod bacteria, which was identified as *P.aeruginosa* after various confirmatory tests.

Discussion

Pseudomonas aeruginosa has been associated with various infections in birds (1,2,3,9,10).

There have been two reports of upper neck subcutaneous lesions due to Marek's disease vaccination contaminated by *P. aeruginosa* in layer chicks (4,11). But in this case, there was not any evidence of injection in history or obvious injury in the back part of the upper neck and the head in the integument examination. Mandibular fracture might be due to improperly manual feeding. Necrosis of the bone may be probably either due to the effects of bacterial toxins or accumulation of exudates in the intertrabecular spaces. In the later case, it may lead to increased intramedullar pressure with subsequent vascular compression and necrosis of the bone tissue and marrow. Acute osteomyelitis can be differentiated from healthy bone marrow and myelopoiesis by the presence of fibrin, heterophils, and other necrotic cells and the absence of hematopoietic tissue. To our knowledge, this is the first report of osteomyelitis associated with *P. aeruginosa*, which may possibly be the cause of feather loss of the head leading to baldness.



References

1. Bailey, T.A., Silvanose, C.D., Naldo, J.N. and Howlett, J.H. (2000) *Pseudomonas aeruginosa* infections in kori bustards (*Ardeotis kori*). Avian Pathol. 29:41-44.
2. Barnes, H.J. (2003) Miscellaneous and sporadic bacterial infections. In Diseases of Poultry. Edited by YM Saif. 11thEd. Iowa State Press. Iowa, USA. pp. 845-862.
3. Hinz, K.H., Kummerfeld, N., Ryll, M. and Braune, S. (2000) Spectrum of bacterial and fungal pathogens in chronic lesions of the upper respiratory tract of psittacine birds. Kleintierpraxis. 45:183-200.
4. Mireles, V., Alvarez, C., Salsbury, S. A. (1979) *Pseudomonas aeruginosa* infection due to contaminated vaccination equipment. Proc. 28th Western Poultry Dis. Conf., USA. pp.55-57.
5. Niall, D.M., Murphy, P.G., Fogarty, E.E., Dowling, F.E. and Moore, D.P. (1997) Puncture wound related pseudomonas infections of the foot in children. Ir. J. Med. Sci. 166:98-101.
6. Rahn, K.A., Jacobson, F.S. (1997) *Pseudomonas* osteomyelitis of the metatarsal sesamoid bones. Am. J. Orthop. 26:365-367.
7. Razmyar, J., Jamshidian, M. (1994) Isolation of *Pseudomonas aeruginosa* from mandibular abscess in a lamb, a case report. Ind. Vet. J. 71:614.
8. Romagnano, A., Heard, D.J. (2000) Avian dermatology. In Manual of Avian Diseases. Edited by GH Olsen and SE Orosz. Mosby Inc. Missouri, USA. pp.95-123.
9. Silvanose, C.D., Bailey, T.A., Naldo, J.L. and Howlett, J.C. (2001) Bacterial flora of the conjunctiva and nasal cavity in normal and diseased captive bustards. Avian Dis. 45:447-451.
10. Silvanose, C.D., Samour, J.H., Naldo, J.L. and Bailey, T.A. (1998) Oro pharyngeal protozoa in captive bustards: clinical and pathological considerations. Avian Pathol. 27:526-530.
11. Trenchi, H., Bellizzi, T. M., De Souza, C. D. (1981) Contamination of Marek's disease vaccine with *Pseudomonas* (achromogenic variety). Gaceta Vet. 43:982-989.

