

B-mode ultrasonography of the udder and teat in camel

(*Camelus dromedarius*)

Abshenas, J.^{1*}, Vosough, D.¹, Masoudifard, M.², Molai, M.M.¹

¹Departemant of Clinical Sciences, Faculty of Veterinary Medicine, University of Shahid Bahonar, Kerman - Iran. ²Departemant of Clinical Sciences, Faculty of Veterinary Medicine, University of Tehran, Tehran - Iran.

Abstract: The aim of the present study was to determine the normal ultrasonographic features of mammary gland and teat parameters in lactating camels. For this study, udders of the ten camels obtained from the local slaughterhouse. B-mode ultrasonographic examination of the udders in the water-bath by 6.5-8.5 MHz linear array transducer was performed. Normal sonographic findings were described and teat canal length, teat end width, teat wall thickness, teat cistern width and middle cistern wall thickness were also measured. Results were analyzed by Paired sample t-test. In the lactating camels, the streak canal, teat sinus, gland sinus and lactiferous ducts were imaged easily. The teat wall could be divided into 3 layers, including a hyperechoic outer layer, a hypoechoic thicker middle layer and a less hyperechoic inner layer. The intercisternal wall of each teat could be divided into 3 layers: two thin hyperechoic outer layers and a thicker hypoechoic middle layer. The B-mode ultrasonography technique as described in this study seems to be reliable for determining the anatomic features of the udder and measuring of the teat parameters of the camel. *J.Vet.Res.* 62,2:27-31,2007.

Key words: camel, ultrasonography, mammary gland.

Introduction

Nowdays B-mode ultrasonography is used extensively as a safe and non-invasive diagnostic technique in veterinary medicine and as a method of choice for detecting reproductive disorders in large domestic animal species (2, 3, 5, 8, 18, 22, 25).

Physiology and diseases of the udder are an important facet of reproduction and production of Camelidae. Camel milk has been a source of nutrients for millions of people in African, Middle-eastern and Asian countries. Several types of camels have been identified as potential "dairy" breeds and can be used as a source of protein for these populations in drought stricken areas. Mammary gland function is also very important for the health and growth of newborns since udder diseases are known to have a negative impact on both these factors and can impose public

health hazards for populations consuming camel milk (15, 21).

Camel has remained neglected in comparison with other livestock species. Some interest and attention have been drawn recently toward camel because of its unique adaptive characteristics for survivability in the desert ecosystem. There are several reports about ultrasonographic evaluation of reproductive tract in the camelids (2, 25, 26). Some investigators have described normal and abnormal ultrasonographic features of the mammary glands, udder structure and teats in cattle, dairy ewes and dairy goats (3, 5, 6, 7, 14, 18, 24). Although they proved that ultrasonography is a valuable system for visualizing changes of the cisternal volume, which allows the internal structure of the mammary gland cistern to be observed clearly, but no ultrasonographic studies of udder and teats of camelids have been found in the literature. The purpose of this study was to determine the normal

*Corresponding author's email: jabshenasmail@mail.uc.ac.ir, Tel: 021-61117125, Fax: 021-66933222



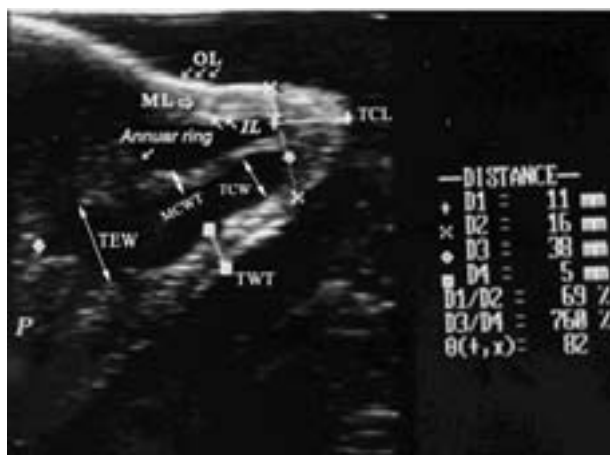

Figure 1: Sagittal scan of the camel teat in a water-bath showing the annular ring as a hyperechoic area. Three layers of the teat wall can be identified. OL (outer layer), ML (middle layer) and IL (inner layer); P (udder parenchyma); TCL (Teat Canal Length); TEW (Teat End Width); TWT (Teat Wall Thickness); MCWT (Middle Cistern Wall Thickness); TCW (Teat Cistern Width). The sonogram was obtained with 7.5 MHz linear array transducer.

ultrasonographic appearance of mammary gland and teat in lactating camels. It is very important for further understanding of the mammary gland problems such as mastitis, obstructive diseases and successful surgical treatment of the affected parts of the udder.

Materials and Methods

Clinically normal udders of 10 lactating camels at different ages (5-12) from slaughtered animals in Rafsanjan abattoir (*camelus dromedarius*) were examined *in situ*, after isolation from the carcasses. The collected udders were immediately transported to Kerman Veterinary Faculty for further ultrasonographic evaluation. One of the teats was attached to a tripod with two clamps; the space between the gland cistern and the teat cistern was filled with 5 ml normal saline. The teats and udders were dipped in a water-bath and examined with B-mode real time ultrasonography by a portable ultrasound machine (Sonoace 600v; Kretz-Technik) equipped with a 6.5-8.5 MHz (7.5 MHz median frequency/60 mm foot print) linear array multi-frequency, waterproof transducer. The transducer was placed in close contact with the glands and teats in the water-bath. Since the teats were not completely circular, the position of the probe on the teats during the experiment was partially held unchanged. The

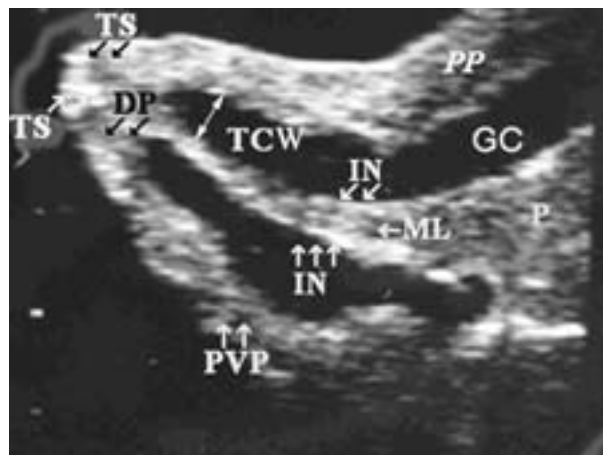

Figure 2: Sagittal scan of the camel teat in a water-bath. TS (teat sphincter), DP (ductus papillaries), TCW (teat cistern width), PP (plexus pempiniferous), GC (gland cistern), P (parenchyma), PVP (plexus venous pempiniferous). Three layers of the intercisternal wall can be identified: IN (inner layers), ML (middle layer). The sonogram was obtained with 8.5 MHz linear array transducer.

glands and teats were scanned in sagittal planes. The teat canal length (TCL), teat end width (TEW), teat wall thickness (TWT), teat cistern width (TCW) and mid cisternal wall thickness (MCWT) were measured in ultrasonographic scans with the electronic calipers and all the images and measurements were recorded on black and white video prints.

SPSS Version 11 was used for obtaining mean and standard deviation of measurements and the data comparison for TCL, TEW, TWT, TCW and MCWT between anterior and posterior teats were analyzed by Paired Sample T-test at $P \leq 0.05$.

Results

In dromedary camelidae, B-mode ultrasonography with 6.5-8.5 MHz linear array transducer in the sagittal plane, showed that each quarter was consisted of two distinct glands, each leading to a separate gland cistern; and each gland cistern connected to the teat cistern, which were completely separated from each other. In the lactating animals, the teat sphincter, teat sinus, annular fold, gland sinus, lactiferous ducts and mammary parenchyma were imaged easily. The teat wall could be divided into 3 layers, a hyperechoic outer layer, a hypoechoic thicker middle layer and a less hyperechoic inner layer (Fig. 1, 2); Furstenberg's



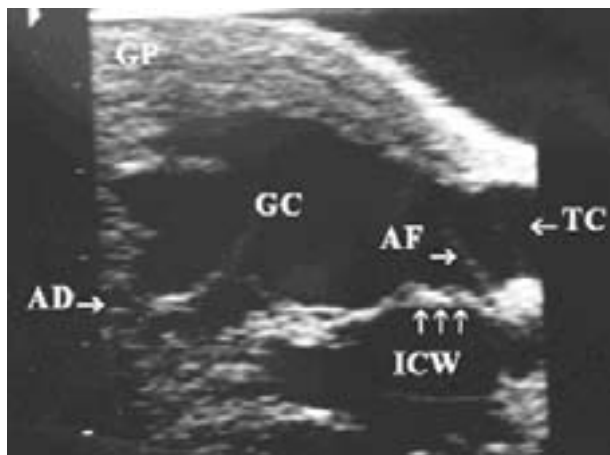


Figure 3: Sagittal scan of the base of the teat showing the alveolar ducts (AD) continues to gland cistern (GC) and two teat cisterns (TC). The glandular parenchyma appears as a hypochoic area (GP). ICW (intercisternal wall), The sonogram was obtained with 6.5 MHz linear array transducer.

rosette was not perceptible. The teat canal appeared unclearly as a linear stria, bordered by the sonographic image of the adjacent teat wall. The base of the teat, the annular folds, appeared as a hyperechoic linear structure extending into the lumen. The glands of sinuses appeared as an anechoic area continuous with the teat sinus. The lining of the wall of the glands sinus appeared as mixed hyper to hypochoic areas within the hypochoic material of the glands (Fig. 3). Multiple small anechoic areas were observed within the middle layer of the teat wall on the images of the 8.5 MHz scan (Fig. 2). The intercisternal wall of each teat could be divided into 3 layers; two thin hyperechoic outer layers and a thicker hypochoic middle layer (Fig. 2). Table 1 shows the results of measurements of teat parameters in anterior and posterior teats. No statistically significant difference ($p > 0.05$) could be found between anterior and posterior teats parameters.

Discussion

The B-mode ultrasonography technique as described in this study seems to be reliable for determining the anatomic features of the udder and measuring the teat parameters of the camel. The method is also relatively easy to use, repeatable, safe and noninvasive. This makes the ultrasound scanning a useful technique to study the teat and udder of camel.

Table1: Ultrasonographic measurements of teat parameters in anterior and posterior quarters of camels.

Teat	Parameter	Mean (\pm SE)	Range (mm)
Anterior teats	TCL	9.33 (0.35)	6.33-12.33
	TEW	14.58 (0.33)	10.58-18.58
	TWT	7.91 (0.49)	2.91-12.91
	TCW	4.66 (0.18)	2.66-8.66
	MCWT	2.75 (0.13)	1.75-3.75
Posterior teats	TCL	9 (0.38)	4-14
	TEW	14.91 (0.28)	11.91-17.91
	TWT	7.75 (0.32)	4.75-10.75
	TCW	4.62 (0.18)	2.62-6.62
	MCWT	2.58 (0.14)	1.58-3.58

Note. The sample numbers were 40; Standard Error=SE, Teat Canal Length=TCL; Teat End Width=TEW; Teat Wall Thickness=TWT; Teat Cistern Width=TCW; Middle Cistern Wall Thickness=MCWT. No statistical differences were observed between anterior and posterior teat parameters.

Ultrasonographic scanning of udder and teat can be performed by direct contacting the transducer with teat or in a water-bath. Direct contact can be easily applied; however, the shape of the teat may change because the teat wall near the probe and the rosette of Furstenberg area can not be seen completely (12, 16). In the current study, therefore, the ultrasonography was performed while the udder and teat were placed in the water-bath. Franz *et al.*, (2001) reported that coupling the probe directly to the teat had satisfactory results, but according to the other investigators the quality of the image was satisfactory only when the teat was held in a water-bath (11, 27). Cartee *et al.*, (1986) observed that the use of the water-bath increased the acoustic impedance difference between the teat wall and the surrounding medium.

When no liquid is given intramammarily, the quality of the image is reduced. Filling the teat with milk (or a natural solution) was considered to be an important factor for obtaining images of high quality (9, 27). Therefore, we administered normal saline into the sinus papillaries. The presence of water in the teat sinus acted similarly as a "window" of acoustic impedance difference for imaging the deeper structures and far wall of the teat (7).

Ultrasonographic findings of the udder of camels were similar to anatomical, histological and contrast



radiographic findings of Saleh et al (1971), Nosier (1974) and Fowler (1998).

The glandular parenchyma of the teats was hypoechoic and the lactiferous ducts appeared as anechoic areas due to their fluid content. Some of the anechoic areas within the glandular parenchyma may have been blood vessels, but others certainly were lactiferous ducts, because they could be seen entering the gland sinuses. Our results are in agreement with the results reported by Cartee *et al.*, (1986) in cows which presented large anechoic areas in the gland sinuses.

It has been reported that milking in camels needs to be performed soon after the teat swelling, since the duration of the milk letdown response is also very short, approximately 1.5 min. Because of this fact, some authors have assumed that camels do not have mammary cisterns (28). The results of this study show the presence of defined gland and teat cisterns in camels.

In camel, the ultrasonographic measurements of TWT, TCL, TCW, TC and MCWT have not been reported yet. In an early report by Saleh *et al.*, (1971), only the length and diameter of the camel udder have been measured manually. Our results were in agreement with this report in the average diameter of the base of the teats.

In conclusion, morphological structure of camel teat and udder can be differentiated with B-mode ultrasound. Since there are several reports of udder infection, udder obstruction and mastitis problems in camels (1, 4, 13, 19, 20), further investigations are necessary to evaluate ultrasonographic images as an additional diagnostic tool for abnormalities of the udder and teat in camels.

Acknowledgements

The authors would like to thank Dr. Mohammadei and Mr. Kafee in Rafsanjan slaughterhouse for their kind assistance in collecting the samples.

References

1. Abdurahman, O.A., Agab, H., Abbas, B., Astrom, G. (1995) Relations between udder infection and somatic cells in camel (*camelus dromedarius*) milk. Acta. Vet. Scand. 36:423-31.
2. Ali, A.M., el-Sanousi, S.M., al-Eknaah, M.A., Gameel, A.A., Dafalla, E.A., Homeida, A.M., Radwan, Y.M. (1992) Studies on the infundibular cysts of the uterine tube in camel (*Camelus dromedarius*). Rev. Elev. Med. Vet. Pays. Trop. 45:243-53.
3. Ayadi, M., Caja, G., Such, X. and Knight, C.H. (2003) Use of ultrasonography to estimate cistern size and milk storage at different milking intervals in the udder of dairy cows. J. Dairy. Res. 70:1-7.
4. Barbour, E.K., Nabbut, N.H., Frerichs, W.M., Al-Nakhli, H.M., Al-Mukayel, A.A. (1985) Mastitis in *Camelus dromedarius* in Saudi Arabia. Trop Anim Health Prod. 17:173-9.
5. Bruckmaier, R.M., Blum, J.W. (1992) B-mode ultrasonography of mammary glands of cows, goats and sheep during alpha- and beta-adrenergic agonist and oxytocin administration. J. Dairy. Res. 59:151-9.
6. Bruckmaier, R.M., Ritter, C., Schams, D., Blum, J.W. (1994) Machine milking of dairy goats during lactation: udder anatomy, milking characteristics, and blood concentrations of oxytocin and prolactin. J. Dairy. Res. 61:457-66.
7. Cartee, R.E., Ibrahim, A.K., McLeary, D. (1986) B-mode ultrasonography of the bovine udder and teat. J. Am. Vet. Med. Assoc. 188:1284-7.
8. Cartee, RE. (1985): An introduction to ultrasound. Auburn. Vet. 40 (2): 7-22.
9. Dinc, D.A., Sendag, S. and Aydin, I. (2000) Diagnosis of teat stenosis in dairy cattle by real time ultrasonography. Vet. Rec. 147: 270-272.
10. Fowler, M.E. (1998) Medicine and surgery of South American camelids: llama, alpaca, vicuna, guanaco. 2nd Ed., Iowa State University Press. Iowa, USA, pp. 252-257.
11. Franz, S., Hofmann-Parisot, M.M. and Baumgartner, W. (2004) Evaluation of three-dimensional ultrasonography of the bovine mammary gland. Am. J. Vet. Res. 65: 1159-1163.



12. Franz, S., Hofman-Parisot, W., Windischbauer, G., Suchy, A. and Bauder, B. (2001) Ultrasonography of the teat canal in cows and sheep. *Vet. Rec.* 149: 109-112.
13. Guliye, A.Y., Van Creveld, C., Yagil, R. (2002) Detection of subclinical mastitis in dromedary camels (*Camelus dromedarius*) using somatic cell counts and the N-acetyl-beta-D-glucosaminidase test. *Trop Anim Health Prod.* 34:95-104.
14. Hirsbrunner, G., Metzger, L., Steiner, A. (1998) Implantation of a reinforced polytetrafluoroethylene vascular graft for treatment of obstructions of the teat and mammary gland cisternae in cattle. *J. Am. Vet. Med. Assoc.* 212:1432-1435.
15. Knoess, K.H., Makhudum, A.J., Rafiq, M. (1986) Milk production potential of the dromedary with special reference to the province of Punjab, Pakistan. *World Anim Rev.* 57:11-21.
16. Neijenhuis, F., Klungel, G.H. and Hogeveen, H. (2001) Recovery of cow teats after milking as determined by ultrasonographic scanning. *J. Dairy Sci.* 84: 2599-2606.
17. Nosier, M.B. (1974) Histological structure of the mammary glands of the one humped camel (*Camelus dromedarius*). *Indian J. Anim. Sci.* 43:639-641.
18. Nudda, A., Pulina, G., Vallebella, R., Bencini, R. and Enne, G. (2000) Ultrasound technique for measuring mammary cistern size of dairy ewes. *J. Dairy Res.* 67:101-106.
19. Obied, A.I., Bagadi, H.O., Mukhtar, M.M. (1996) Mastitis in *Camelus dromedarius* and the somatic cell content of camels' milk. *Res. Vet. Sci.* 61:55-8.
20. Ramadan, R.O., el Hassan, A.M., Abdin-Bey, R., Algasnawi, Y.A., Abdalla, E.S., Fayed, A.A. (1987) Chronic obstructive mastitis in the camel. A clinicopathological study. *Cornell Vet.* 77:132-150.
21. Raymond, H.M. (1994) Camels for meat and milk production in Sub-Sahara Africa. *J. Dairy Sci.* 67:1548-1553.
22. Reef, V.B. (1998) *Equine diagnostic ultrasound.* Philadelphia, Pennsylvania, W.B. Saunders Company.
23. Saleh, M. S., Mobarak, A.M. and Fouad, S.M. (1971) Radiological, anatomical and histological studies of the mammary gland of the one-humped camel (*Camelus dromedaries*) 1- the teat. *Zentralbl Vet. Med. A.* 18: 347-352.
24. Seeh, C., Hospes, R. and Bostedt, H. (1996) Use of visual method (sonography/endoscopy) for the diagnosis of a webbed teat in cattle - a case report. *Tierarztliche Praxis.* 24: 438-442.
25. Tibary, A., Anouassi, A. (1996) Ultrasonographic changes of the reproductive tract in the female camel (*Camelus dromedarius*) during the follicular cycle and pregnancy. *J. Camel Pract. and Res.* 3:71-90.
26. Tinson, A.H., McKinnon, A.O. (1992) Ultrasonography of the reproductive tract of the female dromedary camel. In *Proceedings. 1st Int Camel Conf.* Newmarket R and W Publications, 129-135.
27. Will, S., Wurgau, S.T., Fraunholz, J., Bouabid, C. and Leidl, W. (1990) Sonographische befunde an der papilla mammae des Rindes. *Deutsche Tierarztliche Wochenschrift.* 97: 403-406.
28. Yagil, R., van Creveld, C., Abu-R'Kaik, G. and Merin, U. (1999) Milk "let-down" in camels. *J. Camel Prac. Res.* 6: 27-29.

